

CASE REPORT

Companion or pet animals

Unusual caudal cervical fracture in a dog

Maxime Jean Jacqmin¹  | Arnaud Baldinger¹ | Julie Combet-Curt² | Alexandra Nectoux² | Pierre Moissonnier¹¹ Department of Small Animal Surgery, VetAgroSup, Université de Lyon, Marcy-L'Etoile, Lyon, France² Intensive care unit, SIAMU, VetAgroSup, Université de Lyon, Marcy-L'Etoile, Lyon, France**Correspondence**Maxime Jean Jacqmin, Department of Small Animal Surgery, VetAgroSup, Université de Lyon, 1 Avenue Bourgelat, 69280 Marcy-L'Etoile, Lyon, France.
Email: max.jacqmin@gmail.com**Abstract**

A 14-month-old entire male Saint Bernard dog was presented at the emergency department for paralysis after a head trauma. Computed tomography examination revealed an atypical fracture of C6 with a large free bone fragment in the dorsolateral part of the vertebral canal, originating from the vertebral body. A C6–C7 Funkquist B dorsal laminectomy was performed to remove this intra-canal fragment. A dorsal stabilization using lag screws inserted into the articular facets of C5–C6 and C6–C7 was also performed. The surgical procedure maintained vertebral column stability and allowed a complete functional recovery. The present article exposes the diagnosis and therapeutic management of an original cervical fracture, discusses the choice of a stabilization technique for the caudal cervical spine and the possible underlying predisposing factors that could have led to this unusual fracture.

KEYWORDS

cervical fracture, dogs, dorsal laminectomy, fracture management, neurosurgery, stabilization

BACKGROUND

Cervical vertebral fractures are rare in dogs. They can be associated with either static or dynamic spinal cord compressions that both indicate surgical treatment.¹

In the cervical region, spinal cord decompression can be achieved by a ventral slot, a hemilaminectomy or a dorsal laminectomy, depending on the nature and localization of the compressing material.² Ventral stabilization is most often preferred because of the larger amount of available bone purchase for implants on vertebral bodies.² It can also be achieved dorsally after articular facets (zygapophyseal joints) arthrodesis. To authors' knowledge, this technique is rarely described in the literature and not assessed by any biomechanical study in the dog.²

The reported case presents an unusual vertebral fracture treated by a dorsal cervical approach with a Funkquist B dorsal laminectomy and a cervical facet arthrodesis.

CASE PRESENTATION

A 14-month-old entire male Saint Bernard dog was referred to the emergency department following a trauma that occurred several hours before. The dog ran head-first into a wall and presented immediately after severe pain, and abnormal behaviour and gait.

Upon admission, the dog was nonambulatory. Neurological examination revealed weakness, left hind limb paresis, left forelimb paralysis, and severe cervicalgia. Evaluation

of the cranial nerves revealed no anomaly. Normal patellar reflexes and deficiencies in the thoracic limb withdrawal-flexor reflexes suggested a lesion involving the C6–T2 spinal cord segments. A neck splint was temporarily put in place to restrain cervical movements. Dexmedetomidine (Dexdomitor, Zoetis) at 2 µg/kg, tranexamic acid (Exacyl, Sanofi) at 10 mg/kg and morphine at 0.2 mg/kg were administered intravenously. Dog's behaviour rapidly improved but neck pain was still severe.

INVESTIGATIONS

The computed tomography (CT) scan (General Electric Brightspeed Elite 16-slice helical) of the cervical vertebral column showed a vertebral fracture of the sixth cervical vertebral body (C6) associated with a large (half size of the canal area) compressive bone fragment (14 × 9 × 6 mm) localized in the left dorsal part of the vertebral canal (Figure 1). A bone defect consistent with the fragment morphology and volume was present in the vertebral body, extending from the ventral aspect of the vertebral canal to the ventral cortex of C6.

DIFFERENTIAL DIAGNOSIS**Treatment**

A dorsal approach of the cervical vertebral column was performed from C4 to C7 vertebrae, as described previously.³

LEARNING POINTS/TAKE HOME MESSAGES

- Screwing of the articular facets adds some stability in case of cervical vertebral column fracture; indications when dealing with vertebral fractures are limited to cases with compulsory dorsal approach for dorsal medullar decompression associated with minimal vertebral instability.
- Burst fractures are more often comminutive fractures with likely partial encroachment of the vertebral body into the vertebral canal. Free intracanal bone fragments are exceptions.
- Funkquist B laminectomy can be modified in the cervical column by preserving the spinous processes, in order to limit iatrogenic instability.

Then, according to the CT scan, a minimal Funkquist B dorsal laminectomy of C6 was performed, with a left lateralization, preserving the spinous processes.⁴ A large haematoma was found in the vertebral canal and removed by aspiration. The intra-canal bone fragment was visualized and removed after fragmentation in three portions (Figure 2; Video S1). The spinal cord within its dura mater then regained its central place in the vertebral canal and showed normal appearance.

In order to increase the stability of the affected intervertebral units, standard 3.5-mm screws were inserted in lag fashion in the caudal articular processes (or articular facets) of C5 and C6 and in the cranial joint processes of C6 and C7. A smaller screw (2.7-mm diameter) was inserted from the caudal articular process of C6 to the cranial articular process of C7 on the left because of a fissure discovered in the caudal articular process of C6 (Figure 3). Opening of the joint capsules allowed direct visualization of the facets and helped for good positioning of the screws. The angulation of these screws was

45° caudally in the sagittal plane and 40° laterally in the transverse plane in accordance with preoperative tomodensitometric measurements. The length and diameter of the screws were adapted to the size of the articular processes, in order to leave enough bone purchase all around the screws. Dorsal intervertebral joint congruency and spine stability were noticed after facet joint screwing.

Postoperative radiographs revealed satisfactory alignment of the spine and a good positioning of the implants (Figure 4).

Histological examination of the bone fragment showed focal bone necrosis associated with acute fibrino-haemorrhagic inflammation with numerous mature neutrophils, consistent with the history of vertebral fracture. No sign of neoplastic process was detected.

Outcome and follow-up

Two days after surgery, the dog presented an improvement of his neurologic status by being ambulatory with support and reduced pain because of a multimodal analgesia (methadone, Comfortan, Dechra, 0.1–0.2 mg/kg IV six times a day if pain score >5 out of 18 – 4A-Vet pain scale; meloxicam, Metacam, Boehringer, 0.1 mg/kg IV once a day; gabapentine, Neurontin, 10 mg/kg PO three times a day).

Four days after surgery, the dog presented hyperthermia (from 39.6°C to 40.8°C). Clinical examination revealed bilateral abscess in the oral cavity associated with bilateral mucopurulent nasal discharge and a seroma regarding the surgical wound. Concomitantly, urinalysis and bacterial culture revealed urinary tract infection with an *Escherichia coli*-positive urine culture. Chest x-rays were performed to exclude an aspiration pneumonia and were within normal limits, which supported our hypothesis that the nasal discharge was consecutive to the oral abscess. The surgical wound was partially re-opened to allow intensive wound irrigation. A tie-over bandage was placed, changed every day with use

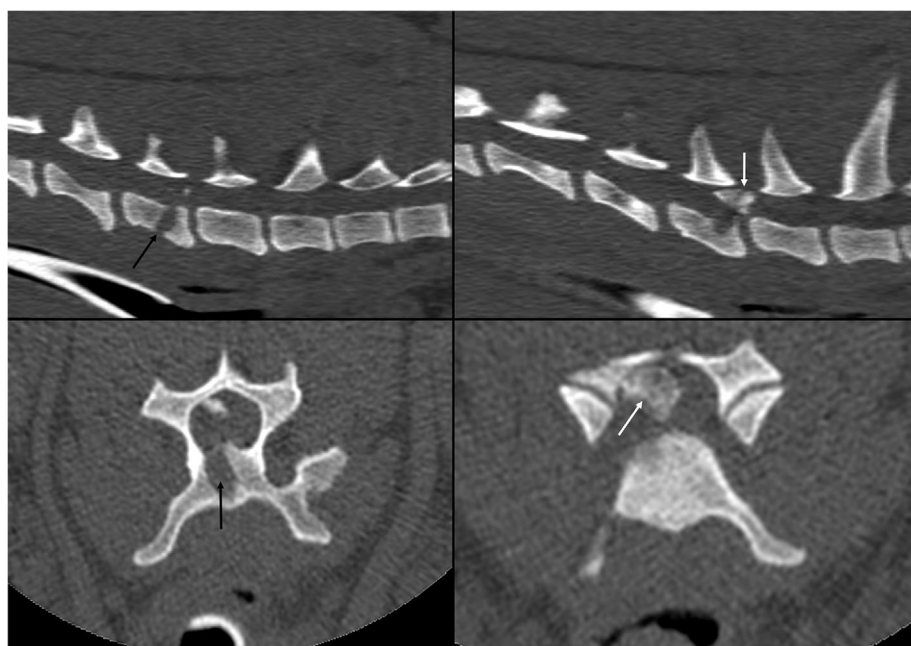


FIGURE 1 Sagittal and transverse sections of the computed tomography (CT) scan revealing a fracture of the central part of the vertebral body of C6 (black arrows) with major encroachment of the spinal canal by a free fragment (white arrows)